

# Cerebral Air Embolism Resulting from Invasive Medical Procedures

## Treatment with Hyperbaric Oxygen

BRIAN P. MURPHY, CAPT, USAF, MC, FRANCIS J. HARFORD, COL, USAF, MC,  
FREDERICK S. CRAMER, COL, USAF, MC

The introduction of air into the venous or arterial circulation can cause cerebral air embolism, leading to severe neurological deficit or death. Air injected into the arterial circulation may have direct access to the cerebral circulation. A patent foramen ovale provides a right-to-left shunt for venous air to embolize to the cerebral arteries. The ability of the pulmonary vasculature to filter air may be exceeded by bolus injections of large amounts of air. Sixteen patients underwent hyperbaric oxygen therapy for cerebral air embolism. Neurological symptoms included focal motor deficit, changes in sensorium, and visual and sensory deficits. Eight patients (50%) had complete relief of symptoms as a result of hyperbaric treatment, five (31%) had partial relief, and three patients (19%) had no benefit, two of whom died. The treatment of cerebral air embolism with hyperbaric oxygen is based upon mechanical compression of air bubbles to a much smaller size and the delivery of high doses of oxygen to ischemic brain tissue.

FROM 1970 TO 1984, 16 cases of cerebral air embolism resulting from invasive medical procedures were treated with hyperbaric oxygen at the United States Air Force School of Aerospace Medicine. Patient data is shown in Table 1. The majority of these patients had serious underlying medical conditions requiring invasive procedures, with cardiovascular disease or malignancy present in nine patients. All but two patients were male, perhaps reflecting the increased incidence of these two categories of disease in males.<sup>1</sup> The age of the patients ranged from 18–78 years, with a mean of 56 years. Percutaneous vascular access, both venous and arterial, cardiopulmonary bypass accidents, and lung biopsy provided the opportunity for air embolism. In-dwelling subclavian vein catheters used for total parenteral nutrition were the most common cause (seven patients), either during the placement of the catheter or as a result of disconnection of the tubing.

*From the United States Air Force School of Aerospace Medicine, Brooks AFB, and the Department of General Surgery, Wilford Hall USAF Medical Center, Lackland AFB, San Antonio, Texas*

The 16 patients in our series all exhibited neurological symptoms as a result of cerebral air embolism. A sudden change in sensorium was the most common presentation, ranging from disorientation to coma. Focal motor deficits, visual changes, and sensory deficits also occurred in several patients. Respiratory arrest, seizures, and severe headache were seen less commonly. The majority of patients developed symptoms immediately, although in some cases the occurrence of cerebral air embolism was not recognized until an explanation was sought for the sudden development of a neurological deficit. In these latter instances, the time interval between embolization of air and onset of symptoms was impossible to determine.

All patients underwent hyperbaric oxygen therapy in a large multiplace chamber accompanied by a physician. Thirteen patients underwent treatment on a compression schedule designed many years ago by the United States Navy to treat cerebral air embolism caused by breath-holding pulmonary overpressure accidents while surfacing from scuba diving. This treatment was one of many compression schedules developed over the years to treat different decompression accidents from diving, and was termed the USN Compression Table 6A (Fig. 1). The pressure is increased to six atmospheres absolute and the patient breathes the air of the chamber for 30 minutes. After decompressing to 2.8 atmospheres, the patient breathes 100% oxygen for 4 hours by a modified aviator's mask that forms a tight seal around the mouth and nose. Oxygen is delivered in 20-minute periods, separated by 5-minute breaks during which the patient removes the mask and breathes the air of the chamber. This intermittent oxygen delivery is designed to reduce

Reprint requests: Brian P. Murphy, Captain, USAF, MC, Wilford Hall USAF Medical Center/SGHSU, Lackland AFB, San Antonio, TX 78236.

Submitted for publication: June 28, 1984.

TABLE 1. Patient Data

| Patient | Age | Primary Diagnosis       | Cause of Air Embolism           | Symptoms  | Time to Hyperbaric Oxygen (Hours) | Response       |
|---------|-----|-------------------------|---------------------------------|---|-----------------------------------|----------------|
| 1       | 18  | Experimental subject    | Brachial artery catheterization | Coma  | 0.2                               | Complete       |
| 2       | 52  | Mitral insufficiency    | Radial artery catheterization   | Coma  | †                                 | None (expired) |
| 3       | 67  | Carotid endarterectomy  | Air into shunt                  | Motor deficit, sensory deficit                          | 2.5                               | Partial        |
| 4       | 63  | Pulmonary infiltrate    | Percutaneous lung biopsy        | Coma, seizures, respiratory arrest                      | 11.0                              | None (expired) |
| 5       | 57  | Carotid endarterectomy  | Temporal artery catheterization | Coma  | 12.0                              | Complete       |
| 6*      | 41  | Carcinoma of lung       | Bronchoscopic lung biopsy       | Coma, respiratory arrest                                | 24.0                              | Complete‡      |
| 7       | 46  | Coronary artery disease | Cardiopulmonary bypass accident | Coma  | 12.0                              | None‡          |
| 8*      | 76  | Mitral insufficiency    | Cardiopulmonary bypass accident | Coma  | 3.0                               | Complete       |
| 9       | 62  | Chronic pancreatitis    | Subclavian vein catheterization | Motor deficit   | 2.0                               | Complete       |
| 10      | 56  | Peptic ulcer            | Subclavian vein catheterization | Motor deficit   | †                                 | Complete       |
| 11      | 23  | Crohn's disease         | Subclavian vein catheterization | Disorientation, visual deficit, chest pain              | 1.0                               | Complete       |
| 12      | 64  | Carcinoma of esophagus  | Subclavian vein catheterization | Loss of consciousness, motor deficit                    | 5.0                               | Partial        |
| 13      | 78  | Carcinoma of colon      | Subclavian vein catheterization | Disorientation, motor deficit                           | 25.0                              | Partial        |
| 14      | 68  | Coronary artery disease | Cardiac catheterization         | Ventricular fibrillation, motor deficit, visual deficit | 3.0                               | Complete       |
| 15      | 57  | Lymphoma                | Subclavian vein catheterization | Headache, sensory deficit                               | 12.0                              | Partial        |
| 16      | 60  | Cholecystitis           | Subclavian vein catheterization | Disorientation, visual deficit                          | 3.0                               | Partial        |

\* Female.

† Not recorded.

‡ Extended "saturation" treatment.

the possibility of central nervous system oxygen toxicity, which can occur while breathing pure oxygen under increased atmospheric pressure and is manifested by grand mal seizures. The "air breaks" allow the high intra-arterial oxygen levels to temporarily drop, and have been effective in minimizing central nervous system (CNS) oxygen toxicity.

The hyperbaric chamber is decompressed to normal atmospheric pressure in stages during the 4 hours of oxygen breathing to prevent re-expansion of resolving air bubbles in the circulation. Further, the physician attending the patient inside the chamber breathes the compressed air of the chamber and accumulates a large amount of nitrogen in his body tissues; a slow, staged decompression allows his accumulated nitrogen to off-gas and prevents decompression sickness in the attendant. Three patients underwent prolonged variations of this compression table, due to the severity of their symptoms. Two patients underwent "saturation treatment," in which they were compressed to three atmospheres breathing air for 10 hours or more. The nitrogen saturation with this treatment necessitates a very prolonged decompression period, so that the whole treatment lasted 72 hours.

A determination of response to therapy was made. Eight of 16 patients (50%) became asymptomatic while undergoing or shortly after completing hyperbaric therapy. Five patients had partial resolution of symptoms (31%). Three patients had no response; two of these died while in the hyperbaric chamber and the third was left with a severe neurological deficit. Overall mortality was 13%.

The time delay between occurrence of air embolism and initiation of hyperbaric treatment was recorded in 14 patients, ranging from 10 minutes to 25 hours, with a mean of 8.25 hours. The number of patients is too small to allow statistical correlation between time delay and response to therapy. However, the group judged to have a complete response averaged 6.5 hours from the time of incident to the time of therapy, and the partial responders averaged 9.5 hours delay. Time delay was determined in two of the three nonresponders to be 11 and 12 hours. Of the eight patients whose time delay was 5 hours or less, five (63%) had a complete response. Of the six patients whose delay to treatment was greater than 5 hours, only two (33%) had a complete response.

In our series both arterial and venous access led to

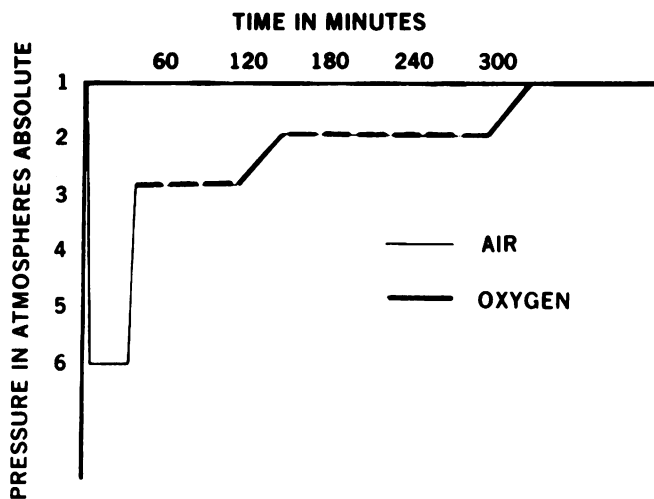


FIG. 1. United States Navy Compression Table 6A, modified. Oxygen breathing is broken up into 20-minute periods to reduce the possibility of oxygen toxicity seizures.

embolization of air. The following case reports represent these two phenomena.

**Case 1.** A 67-year-old insulin-dependent diabetic man with severe coronary artery disease underwent cardiac catheterization in preparation for coronary artery bypass grafting. While the tip of the catheter was in the left ventricle, 10–20 cc of air was accidentally injected from a syringe that should have been filled with iodine contrast solution. Air was seen in the left ventricle on fluoroscopy. The patient immediately developed ventricular tachycardia, progressing to ventricular fibrillation and cardiac arrest, secondary to air in the coronary arteries. He was cardioverted and successfully resuscitated from his cardiac arrest in less than a minute. However, he had marked weakness in the left arm and was unable to raise his left leg or flex the knee or ankle. He was also blind in the right eye. These findings were indicative of cerebral air embolism *via* the right carotid artery and he was transported to the hyperbaric chamber. At the start of compression therapy, 3 hours after the incident, he had slight improvement in vision of the right eye but no improvement in motor strength of the affected extremities. Compression to six atmospheres was performed. During 30 minutes of breathing air at that pressure, his vision returned to normal and there was partial improvement in the motor strength of the affected extremities. During the following 4 hours of intermittent oxygen breathing he had progressive improvement in motor function. At the end of the treatment, he had only a slight weakness in left hand grip and no visual or lower extremity deficit. Over the next 2 weeks, his hand strength returned to normal and he underwent successful coronary artery bypass grafting 2 months later.

**Case 2.** A 22-year-old man with severe Crohn's disease was placed on bowel rest and total parenteral nutrition by an in-dwelling subclavian vein catheter. After the catheter had been in place for several days, the tubing became disconnected from the hub of the catheter while the patient was in the upright position. The patient noticed leakage of fluid from the catheter and immediately developed symptoms of substernal chest pain and shortness of breath, followed by scintillating scotomata, confusion, dizziness, and vertigo. He was given mask oxygen and transported to the hyperbaric chamber. Compression therapy was started approximately 1 hour and 20 minutes postincident. The patient's sensorium began to clear immediately and after 12 minutes of breathing air at six atmospheres he was completely free of symptoms. He continued the oxygen-breathing portion of the Table 6A and remained asymptomatic during the remainder of compression therapy.

## Discussion

These two cases illustrate cerebral air embolism resulting from invasive procedures involving both arterial and venous access. Arterial air may have direct access to the cerebral circulation. Venous air may also readily cause cerebral air embolism in the presence of a patent foramen ovale.<sup>2,3</sup> A recent autopsy study found a 27.3% incidence of patent foramen ovale in the general population, and an incidence of 34% in the first 3 decades of life.<sup>4</sup> If a bolus of air lodges in the pulmonary arteries and causes obstruction to pulmonary outflow, a hemodynamically significant right-to-left shunt through a patent foramen ovale is likely to occur, with subsequent cerebral air embolism.

In the absence of a patent foramen ovale, venous air must traverse the pulmonary vasculature to enter the cerebral circulation. The pulmonary arterioles and capillaries are generally considered an effective filter for thrombi, platelet aggregates, and fat emboli, but trapping of air may not be so effective.<sup>5</sup> Marquez reported a fatal cerebral air embolism resulting from a neurosurgical procedure in which postmortem examination detected no intracardiac septal defects.<sup>6</sup> Butler demonstrated in a canine model that the lung is normally a very effective filter for air bubbles of greater than 22 micrometers in diameter when infused slowly.<sup>7</sup> However, a bolus injection of 30 cc of air into a central vein exceeded the filtering capacity of the lung and produced embolization through the left heart and into the arterial circulation. Spencer subjected unanesthetized sheep to slow venous injections of oxygen and nitrogen.<sup>8</sup> Oxygen injected into the jugular vein at a rate of 0.15 ml/kg/min produced bubbles detectable by Doppler perivascular flow transducer in the brachiocephalic artery in one of five animals. Nitrogen injected at the same rate caused arterial embolization in three of five animals. An elevation in pulmonary arterial pressure and a decrease in systemic arterial PO<sub>2</sub> accompanied the arterial bubbling. No signs or symptoms of systemic effects were noted until large (unspecified) quantities of air were injected. Paralysis, unconsciousness, and death occurred after massive embolization. Postmortem examination revealed no cardiac shunts in any of the animals. Although this animal model has limitations in its application to cerebral air embolism in humans, the injection rate into the jugular vein at which intra-arterial bubbles were detected is equivalent to a 10.5 ml/min air injection in a 70-kg human. The ability of the lung to filter air may be exceeded by rapid introduction of large quantities of air during invasive medical procedures.

In the acute phase of cerebral air embolism, it is unwise to delay treatment in order to document the existence of intravascular air. The temporal relationship between the injection of air and the sudden development of neurological symptoms must lead one to a presumptive

diagnosis. Immediate therapeutic measures include the administration of oxygen to reverse cerebral ischemia and Trendelenburg position to enhance retrograde flow of bubbles from the cerebral arteries. In the case of air embolism *via* a subclavian vein catheter, advancement of the catheter into the heart to withdraw air from the right ventricle has been recommended.<sup>9</sup>

The rationale for hyperbaric oxygen therapy is based on compression of air bubbles to mechanically clear the cerebral circulation and oxygenation of ischemic tissues with large volumes of oxygen dissolved in plasma. According to Boyle's Law, the volume of a gas is inversely proportional to the pressure exerted on that gas. Compression to six atmospheres will reduce the size of an air bubble obstructing a blood vessel to one-sixth of its original volume, effectively relieving the obstruction and restoring perfusion (Fig. 2). As foreign bodies, intravascular air bubbles incite an acute inflammatory response with platelet aggregation and the release of vasoactive amines. The reduction in surface areas as a bubble is compressed minimizes the acute inflammation caused by blood/bubble interaction.

Delivery of high levels of oxygen is also important in the hyperbaric therapy of cerebral air embolism. Breathing 100% oxygen at 2.8 atmospheres produces an alveolar PO<sub>2</sub> of 2041 mmHg. This inspired oxygen tension leads to a measured arterial PO<sub>2</sub> level of 1800 mmHg. Since hemoglobin is nearly completely saturated at sea level, very little additional oxygen can be carried on hemoglobin. The majority of the additional oxygen delivered is dissolved in plasma. At 2.8 atmospheres, oxygen solubility in plasma is 6 ml of oxygen per 100 ml of plasma. These high levels of oxygen help reduce cerebral ischemia as the compressed air bubbles are being resolved, and facilitate the diffusion of small air bubbles from the pulmonary capillaries to the alveoli for elimination. There is also experimental evidence to suggest that cerebral edema is decreased by hyperbaric oxygen due to vasoconstriction caused by hyperoxia.<sup>10,11</sup> Reduction of increased intracranial pressure in severe cerebral ischemia secondary to air embolism may be an added benefit of hyperbaric oxygen therapy.

### Conclusion

Sixteen patients with cerebral air embolism resulting from invasive medical procedures underwent treatment with hyperbaric oxygen. This diagnosis requires a high index of suspicion, and the temporal relationship between injection of air and the sudden development of neurological deficit may be the only criterion. Of 16 patients, eight received complete relief of symptoms and five received partial relief with hyperbaric oxygen therapy. Although this retrospective review relates anecdotal experience, the rapid reversal of symptoms in those patients who responded to therapy is indicative of the benefit of

| PRESSURE IN ATMOSPHERES | RELATIVE VOLUME | RELATIVE SURFACE AREA |
|-------------------------|-----------------|-----------------------|
| 1                       | 100%            | 100%                  |
| 6                       | 17%             | 30%                   |

FIG. 2. Relative volume and surface area of an air bubble with compression to six atmospheres.

hyperbaric oxygen in this condition. Prevention of cerebral air embolism by meticulous technique in the performance of invasive procedures and preservation of the integrity of in-dwelling vascular access catheters is essential. However, the steady growth in the application of percutaneous and endoscopic procedures, total parenteral nutrition, cancer chemotherapy, hemodynamic monitoring, and other invasive procedures will continue to provide opportunities for the accidental injection of air. Hyperbaric oxygen therapy is based on sound physiologic principles of compression of air bubbles and delivery of high doses of oxygen to ischemic neurologic tissues. With an increasing number of hyperbaric chambers in both civilian and military medical facilities, physicians should be aware of the benefits of hyperbaric oxygen in cerebral air embolism and pursue prompt treatment in symptomatic cases.

### References

- Silverberg E. Cancer statistics, 1984. *Cancer* 1984; 34:7-23.
- Gronert GA, Messick JM, Cucchiara RF, Michenfelder JD. Paradoxical air embolism from a patent foramen ovale. *Anesthesiology* 1979; 50:548-549.
- Michel L, Poskanzer DC, McKusick KA, et al. Fatal paradoxical air embolism to the brain: complication of central venous catheterization. *J Parent Enter Nutr* 1982; 6:68-70.
- Hagen PT, Scholz DG, Edwards WD. Incidence and size of patent foramen ovale during the first ten decades of life: an autopsy study of 965 normal hearts. *Mayo Clin Proc* 1984; 59:17-20.
- Heinemann HO, Fishman AP. Nonrespiratory functions of the mammalian lung. *Physiol Rec* 1969; 49:1-47.
- Marquez J, Sladen A, Gendell H, et al. Paradoxical cerebral air embolism without an intracardiac septal defect. *J Neurosurg* 1981; 55:997-1000.
- Butler BD, Hills BA. The lung as a filter for microbubbles. *J Appl Physiol* 1979; 47:537-543.
- Spencer MP, Oyama Y. Pulmonary capacity for dissipation of venous gas emboli. *Aerospace Med* 1971; 42:822-827.
- Coppa GF, Gouge TH, Hofstetter SR. Air embolism: a lethal but preventable complication of subclavian vein catheterization. *J Parent Enter Nutr* 1981; 5:166-168.
- Sukoff MH, Hollin SA, Espinosa OE, Jacobson JH. The protective effect of hyperbaric oxygenation in experimental cerebral edema. *J Neurosurg* 1968; 29:236-239.
- Miller JD, Ledingham IM. Reduction of increased intracranial pressure: comparison between hyperbaric oxygen and hyperventilation. *Arch Neurol* 1971; 24:210-216.